

Original Article

# Observational Study of Pterygoid, Zygomatic and Subperiosteal Implants: Treatment Strategies, Clinical Outcomes, and Complications for Severe Maxillary and Mandibular Atrophy

Abdulmajid Elshawesh<sup>1</sup>, Tarek Esmail\*<sup>2</sup>, Khaled Ben Salah<sup>1</sup>, Kamal Elsebsi<sup>3</sup>, Abduladim Affat<sup>4</sup><sup>1</sup>Oral and Maxillofacial Surgery Department, Faculty of Dentistry, Misrata University, Libya<sup>2</sup>Faculty of Medicine, Alrazi University, Misrata, Libya<sup>3</sup>Alkamal Dental Hospital, Misrata, Libya<sup>4</sup>Department of Health Services, Misrata, LibyaCorresponding Email: [benesmail@yahoo.co.uk](mailto:benesmail@yahoo.co.uk)

## Abstract

Rehabilitation of edentulous atrophic jaws remains a significant clinical challenge. Conventional bone grafting with implant placement often results in extended treatment times, increased morbidity, and higher costs. Graft-less implant rehabilitation, using pterygoid, zygomatic, and subperiosteal implants, offers a minimally invasive alternative for patients with severe maxillary or mandibular atrophy. This study aimed to compare the clinical outcomes, complications, and treatment strategies of pterygoid, zygomatic, and subperiosteal implants in the graft-less rehabilitation of severely atrophic jaws. A total of 15 partially and fully edentulous Libyan patients (age range: 39–63 years) with severe maxillary and mandibular atrophy were treated using a graft-less approach. Implants included 11 zygomatic, 7 pterygoids, and 6 subperiosteal systems. Demographic, surgical, and follow-up data were analyzed. Clinical success, osseointegration, and postoperative complications were evaluated over follow-up periods of 1–25 months. All implant types demonstrated high success rates with no cases of implant loss or persistent infection. Minor complications included transient oral–antral communication in one zygomatic case and small plate exposure in one subperiosteal case. Patient satisfaction was universally high regarding function, comfort, and esthetics. Immediate or early loading was feasible in selected cases with adequate primary stability. Pterygoid, zygomatic, and subperiosteal implants represent reliable, minimally invasive, and cost-effective options for the rehabilitation of edentulous atrophic jaws without the need for bone grafting. Selection of the optimal implant type should be guided by anatomical limitations, bone availability, and patient-specific factors.

**Keywords:** Pterygoid Implant, Zygomatic Implant, Subperiosteal Implant, Atrophic Maxilla.

Received: 04/03/26

Accepted: 03/05/26

Published: 10/05/26

**Copyright:** Author (s)  
2026. Distributed under  
Creative Commons CC-BY  
4.0

## Introduction

Edentulism in patients with severe maxillary or mandibular atrophy presents one of the most demanding challenges in implant dentistry. Progressive alveolar bone resorption following tooth loss, trauma, or pathology can severely compromise bone height and density, particularly in the posterior maxilla, where proximity to the maxillary sinus further restricts implant anchorage [1, 2]. Traditional rehabilitation techniques often involve autogenous or allogenic bone grafting, sinus floor augmentation, or ridge expansion before implant placement [3,4]. While effective, these methods are associated with extended treatment duration, increased morbidity, donor site complications, and high costs [5].

In recent years, graft-less implant strategies—especially pterygoid, zygomatic, and subperiosteal implants—have gained significant attention as alternatives to bone grafting [6-9]. These implants engage dense cortical regions of the craniofacial skeleton, providing enhanced primary stability and allowing for immediate or early loading [10, 11].

Zygomatic implants, introduced by Brånemark in 1989, utilize the dense zygomatic bone for anchorage and are ideal for cases with severe posterior maxillary resorption [12,13]. Pterygoid implants, first described by Tulasne, are inserted into the pterygoid process of the sphenoid bone, avoiding sinus elevation while providing posterior support [14]. Subperiosteal implants, custom-fitted over the alveolar ridge beneath the periosteum, have recently been revived with the aid of digital imaging and 3D printing, offering viable solutions for both maxillary and mandibular atrophy [14,15]. This study presents an observational evaluation of clinical outcomes, complications, and treatment strategies of three graft-less implant modalities in the rehabilitation of 15 Libyan patients with severe atrophic jaws.

## Materials and Methods

### *Study Design and Patient Selection*

This clinical observational study was based on institutional datasets representing fifteen consecutive patients presenting with severe maxillary and/or mandibular atrophy who were treated with one of three graft-less implant modalities, namely zygomatic, pterygoid, or subperiosteal implants, followed by screw-retained bridge rehabilitation between 2023 and 2025 at private dental clinics in Misrata city, Libya. Ethical approval for the study was obtained from the institutional review board of Alkamal Dental Hospital, and informed consent was secured from all participating patients before treatment.

Patients were included if they presented with complete or partial edentulism associated with severe maxillary or mandibular atrophy classified as Cawood and Howell Class V or VI, demonstrated adequate systemic health to undergo oral surgical procedures, and showed no evidence of acute infection or pathological conditions at the intended implant sites. Patients were excluded from the study if they had a history of head and neck radiation therapy, uncontrolled systemic diseases such as diabetes mellitus or osteoporosis, or active maxillary sinusitis. These inclusion and exclusion criteria ensured a consistent and reliable patient population for evaluating the clinical outcomes of the three implant modalities.

### *Patient Demographics*

The study population consisted of fifteen patients, including four males and eleven females, with an age range of 39 to 63 years and a mean age of 52.4 years. Among the female patients, five individuals (45.5%) presented with controlled systemic conditions, including diabetes mellitus or hypothyroidism, which were deemed compatible with surgical intervention.

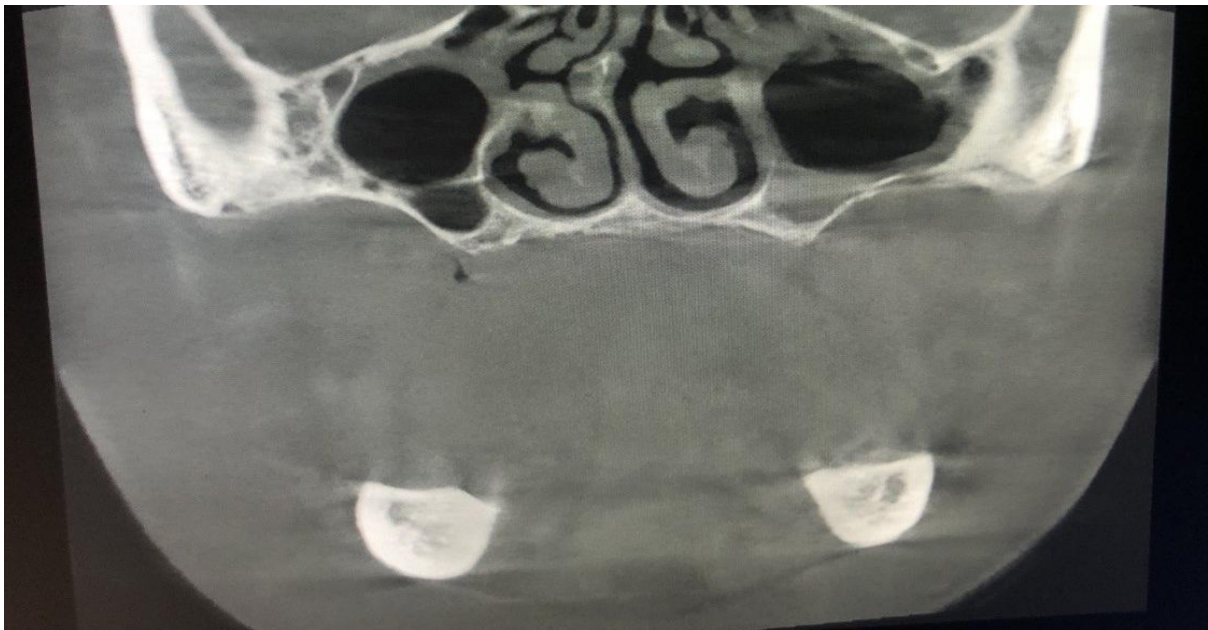### *Implant Types and Distribution*

A total of twenty-four implants were placed during the study period, comprising eleven zygomatic implants, seven pterygoid implants, and six subperiosteal implants. Of these, twenty-one implants were inserted in the maxilla, while three implants were placed in the mandible.

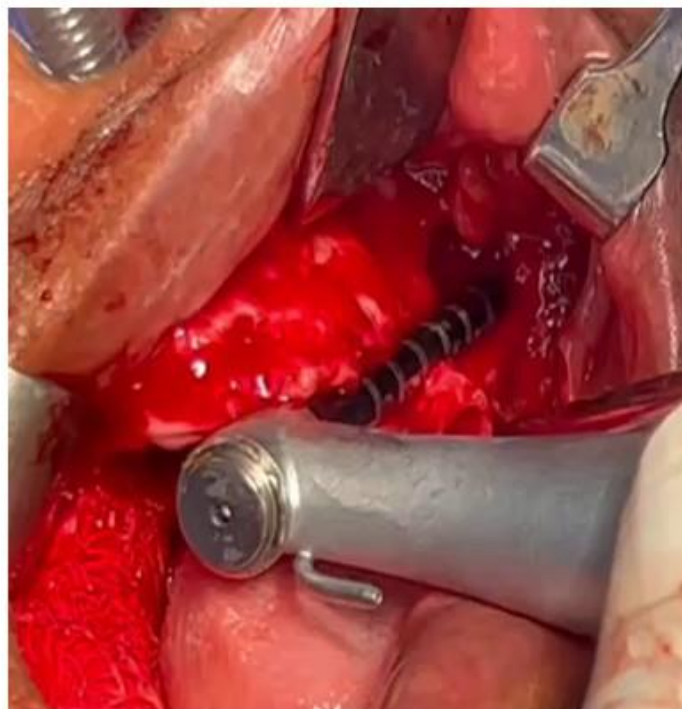### *Surgical Protocols*

#### *Zygomatic Implants*

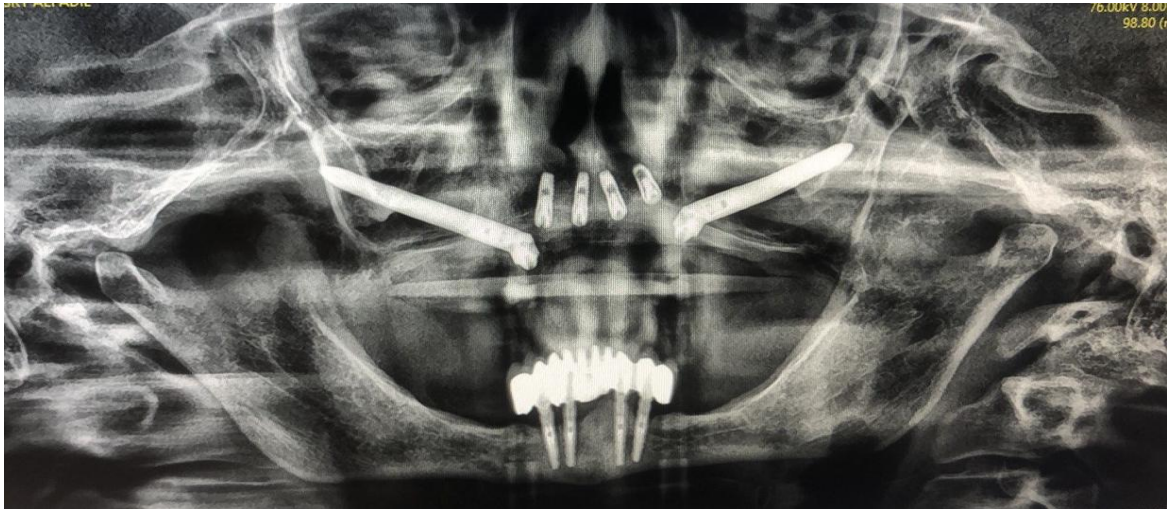
Cone-beam computed tomography (CBCT) was routinely used to evaluate the degree of alveolar ridge atrophy and to assist in preoperative planning, as illustrated in Figure 1. All surgical procedures were performed under general anaesthesia. The implant trajectory originated from either the alveolar crest or the lateral wall of the maxilla and was directed toward the zygomatic bone, as demonstrated in Figure 2. Depending on the level of primary stability achieved, defined as greater than 35 Ncm, either a two-stage protocol or an immediate loading approach was adopted. Postoperative orthopantomograms (OPG) were obtained to confirm correct implant positioning, as shown in Figures 3–7.



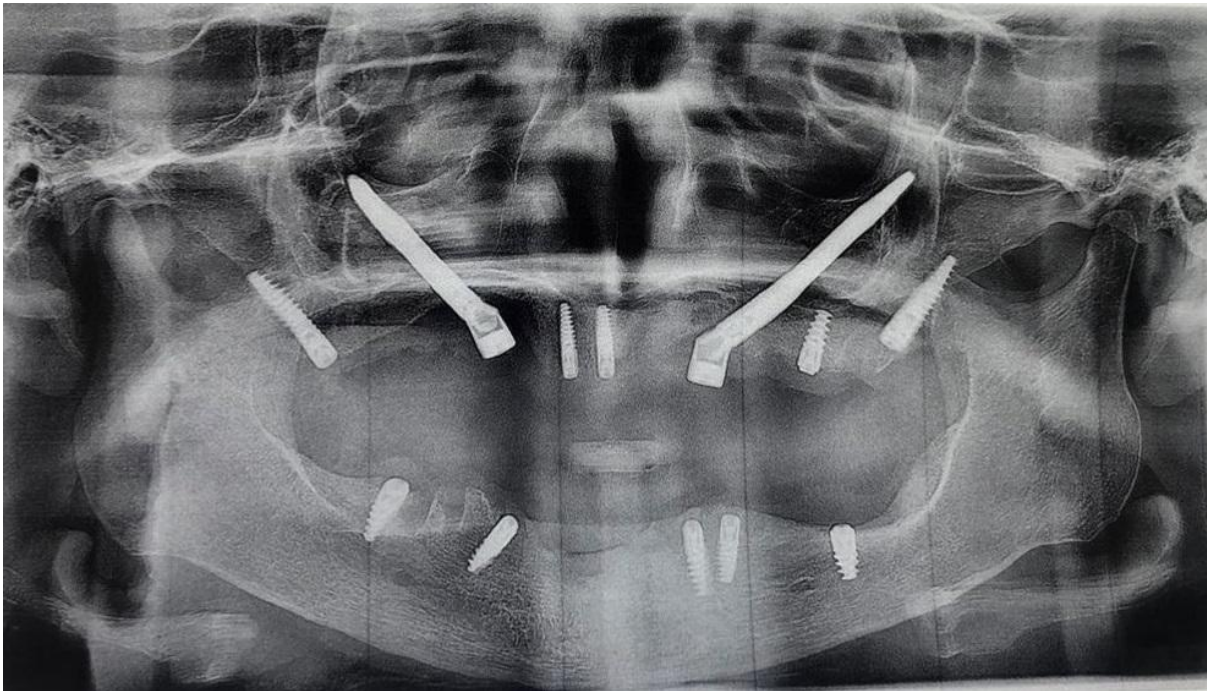
*Figure 1. Coronal section of cone-beam computed tomography (CBCT) image showing severe bone resorption in the maxilla of one of the cases that received zygomatic implant placement.*



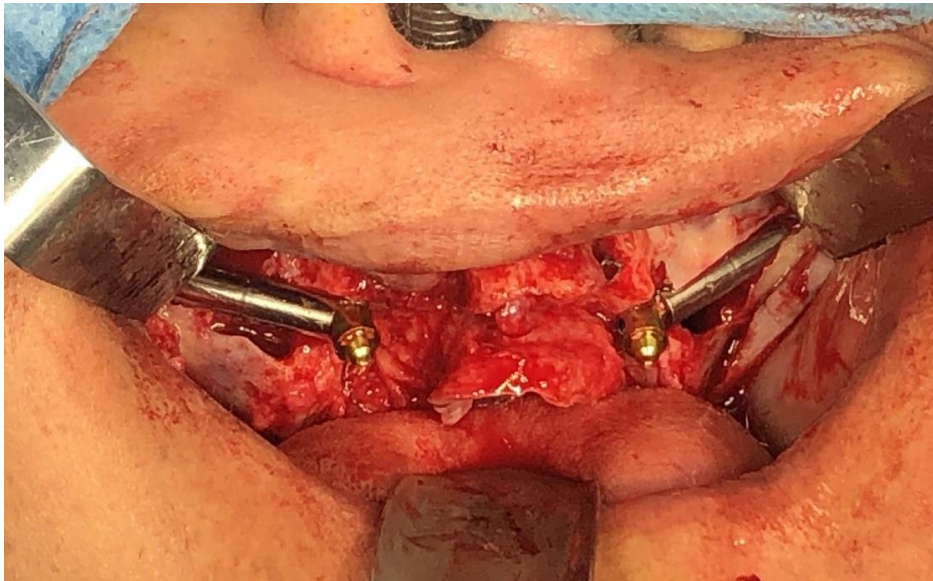
*Figure 2. Clinical photo shows Zygomatic implant osteotomy.*



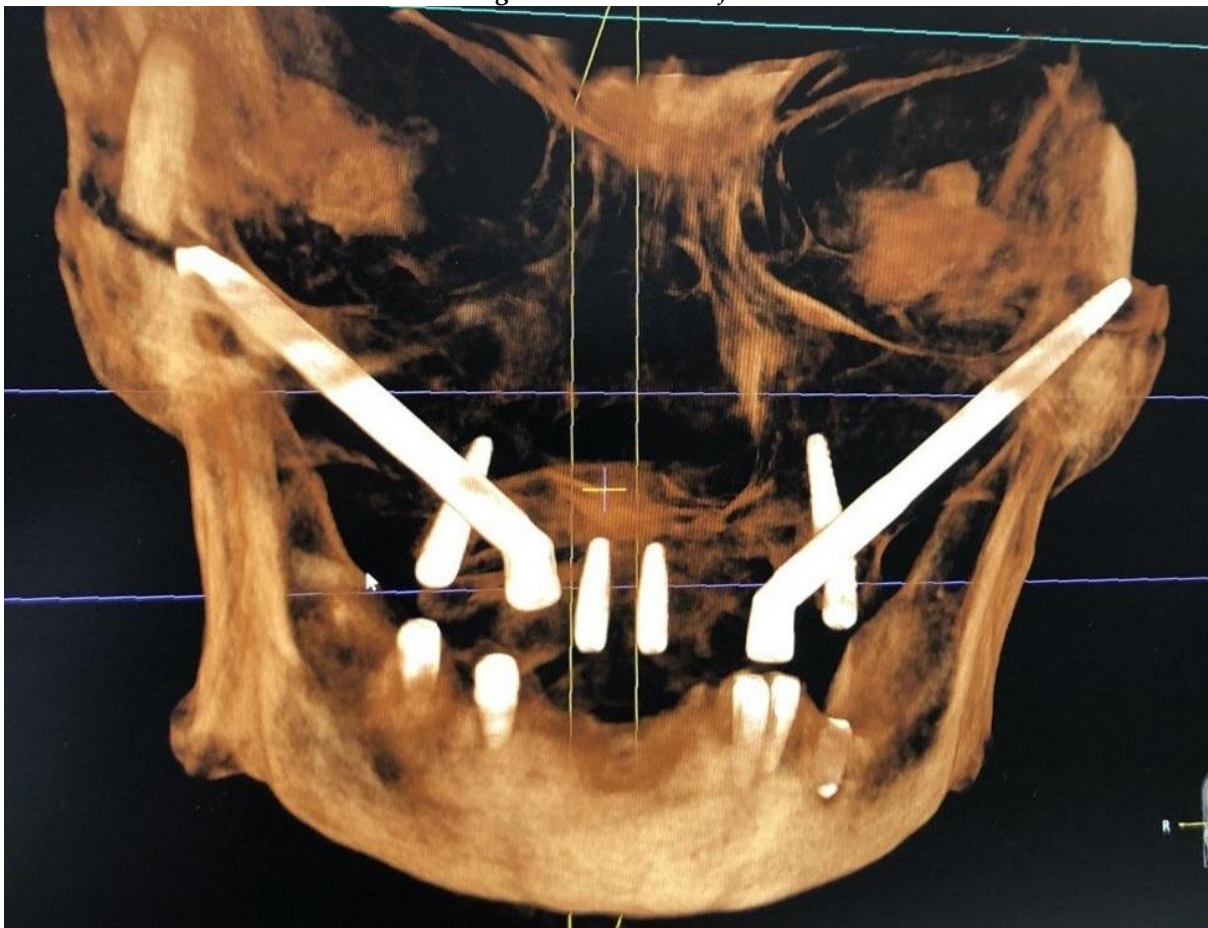
*Figure 3. Postoperative OPG shows zygomatic implants in their positions.*



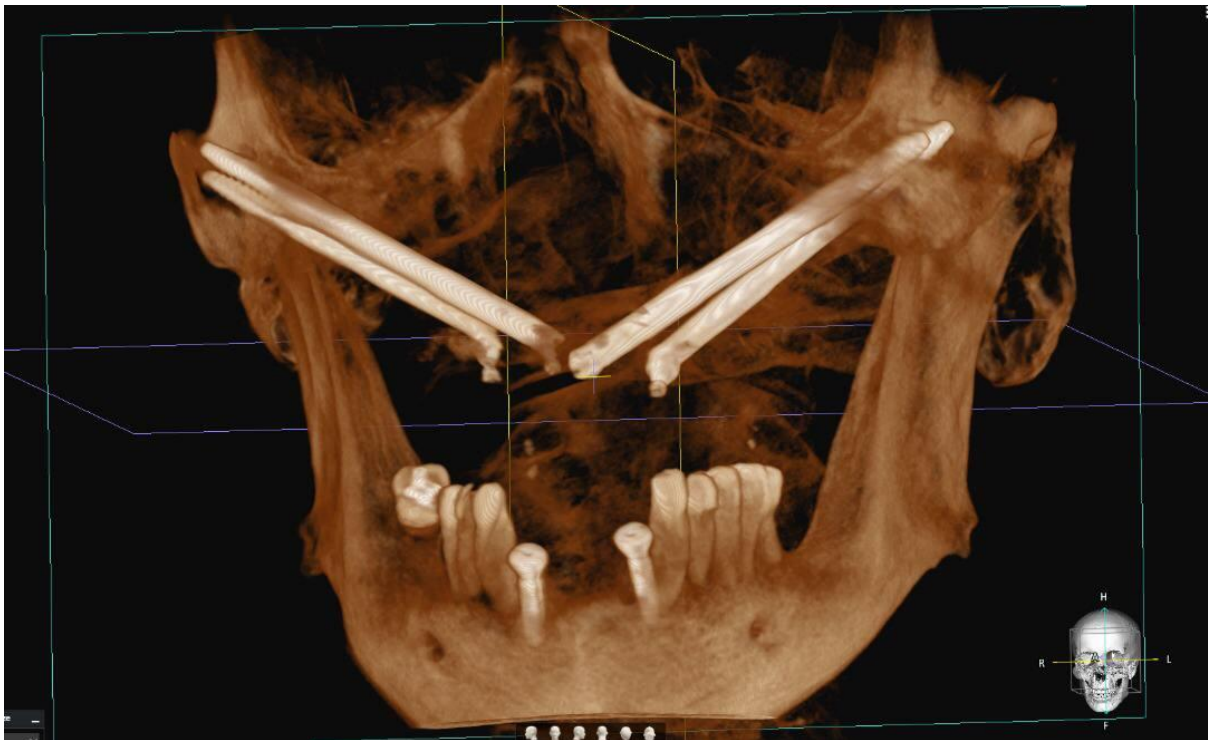
*Figure 4. Pre-prosthetic panoramic radiograph showing maxillary and mandibular full-arch implant placement, including tilted zygomatic and pterygoid implants designed to enhance anteroposterior spread and optimize load distribution.*



*Figure 5. Clinical photo shows intra-operative zygomatic implant placement with multiunit abutments. The right side abutment with 52° angulation and the left side abutment with 45°.*



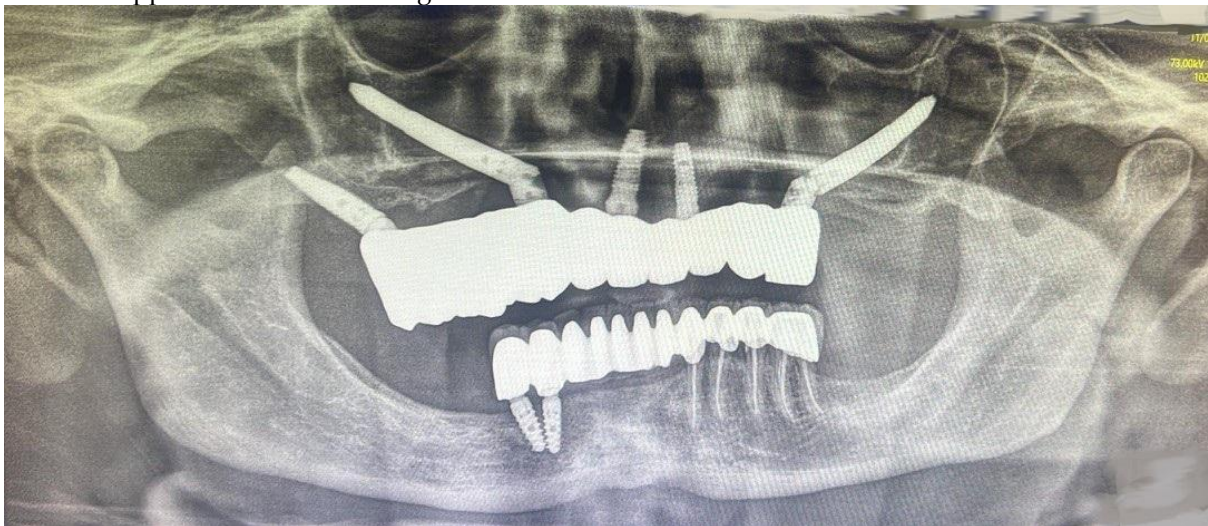
*Figure 6. "Cone beam computed tomography (CBCT) image illustrating three-dimensional assessment of zygomatic implant placement, demonstrating implant angulation, spatial distribution, and their relationship to surrounding anatomical structures."*



*Figure 7. Postsurgical cone-beam computed tomography (CBCT) 3D rendering after placement of quad-zygomatic implants.*

#### ***Pterygoid Implants***

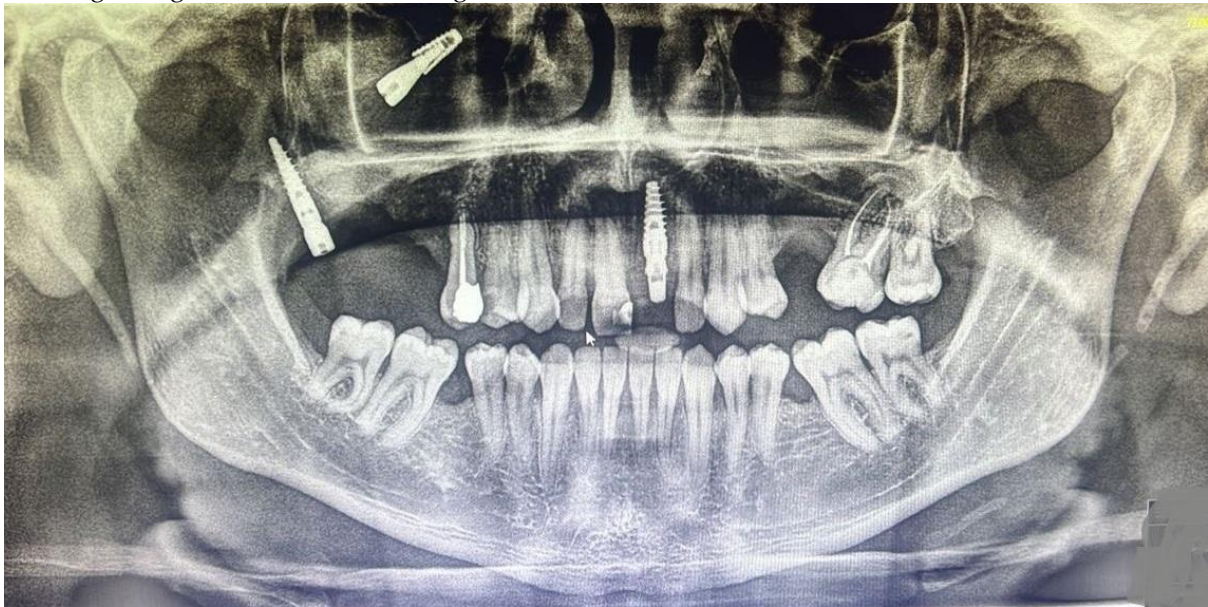
Implants were inserted posteriorly at an angle of approximately 45–55°, engaging the pterygoid process of the sphenoid bone and the pyramidal process of the palatine bone. This approach avoided sinus elevation and provided distal prosthetic support as illustrated in Figure 8.



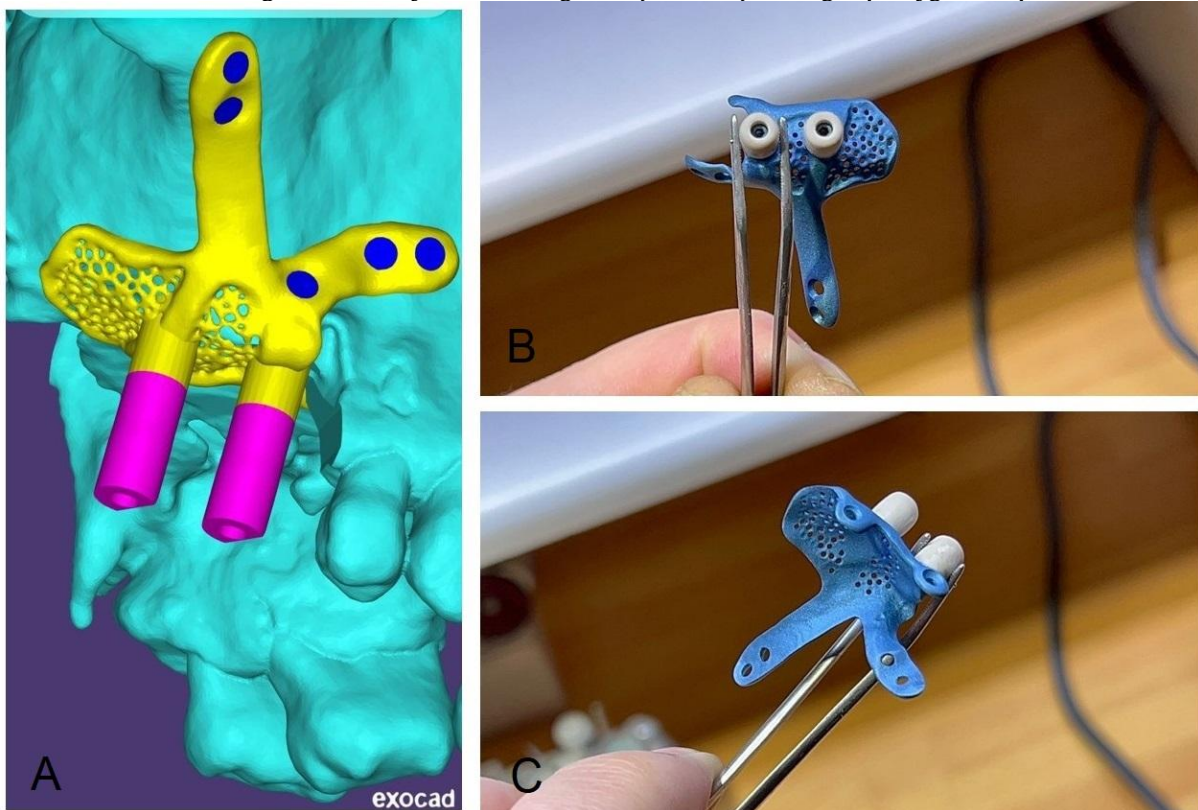
*Figure 8. Two years "Postoperative orthopantomogram (OPG) demonstrating full-arch implant-supported fixed prosthetic rehabilitation in the maxilla and mandible, with a combination of axial and posteriorly tilted implants providing stable prosthetic support and optimized load distribution."*

Subperiosteal implants, particularly contemporary additively manufactured three-dimensional printed designs, represent an effective graft-less treatment option for the rehabilitation of severely atrophic maxillae, including complex cases in which previous implant therapies such as conventional endosteal or pterygoid implants have failed. As illustrated in Figure 9, a postoperative orthopantomography demonstrates the clinical course of a female patient who initially received an implant to replace the missing maxillary right first molar, which failed to achieve osseointegration

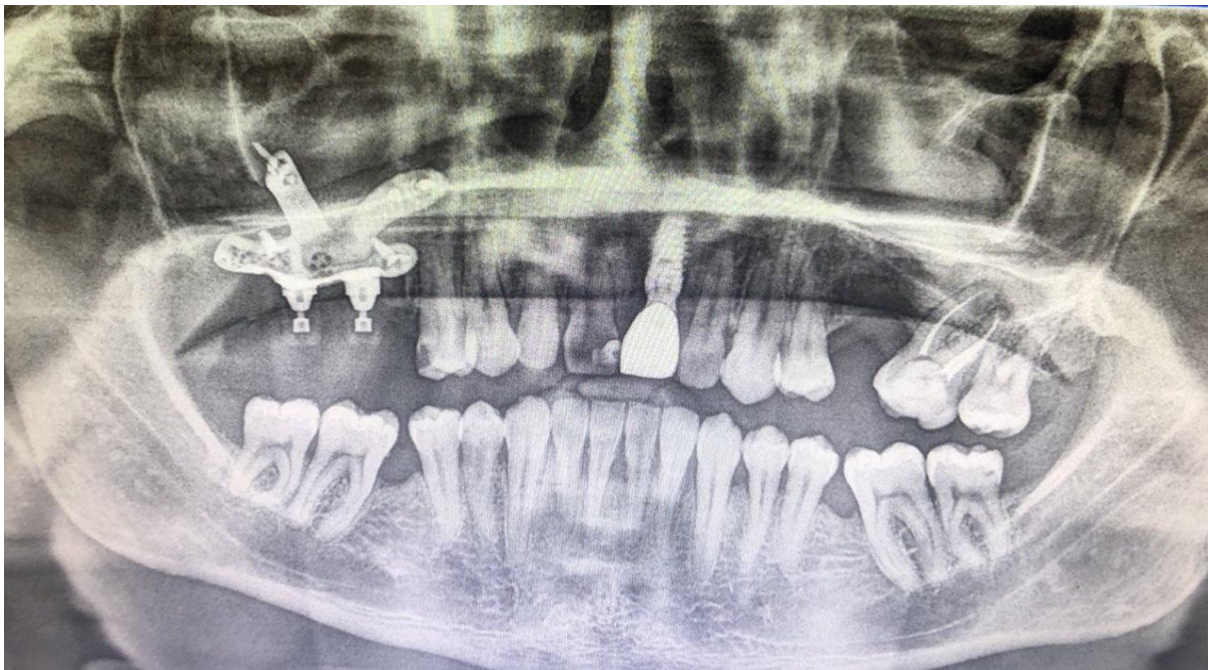
and subsequently migrated into the maxillary sinus, while a later rehabilitation attempt using a pterygoid implant was also unsuccessful. Following the removal of both failed implants, the affected region was successfully rehabilitated using a subperiosteal implant, which provides a patient-specific titanium framework positioned on the bone surface beneath the periosteum, thereby achieving stable fixation in areas with limited bone volume without the need for extensive bone grafting, as demonstrated in Figures 10–14.



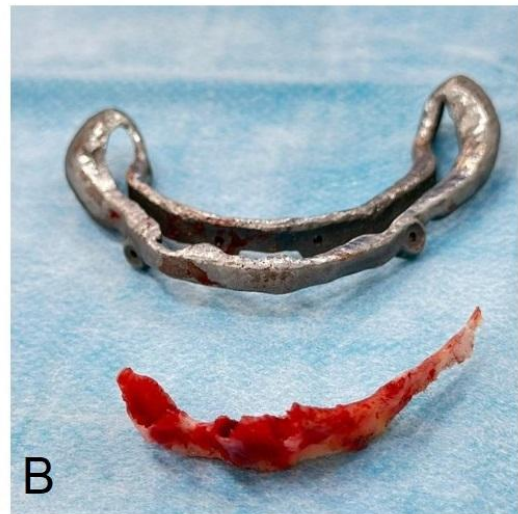
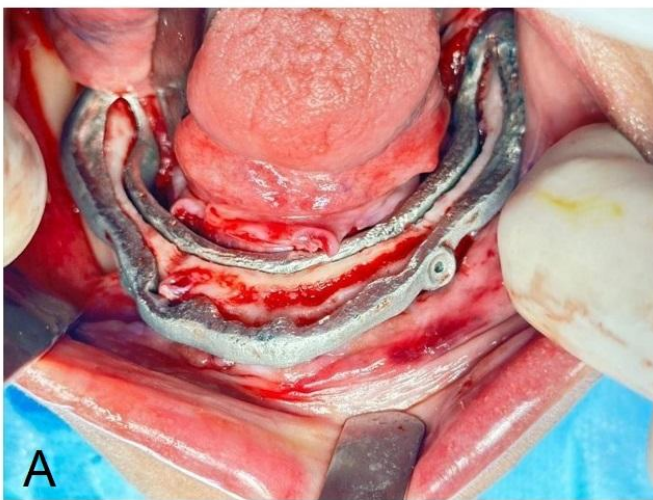
*Figure 9. Postoperative orthopantomogram demonstrating a completely displaced implant with a healing abutment within the right maxillary sinus, along with failure of the right pterygoid implant.*



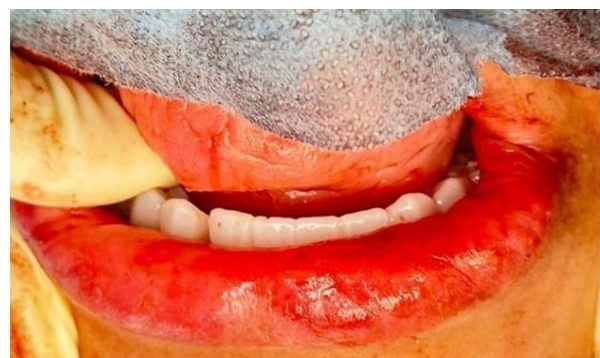
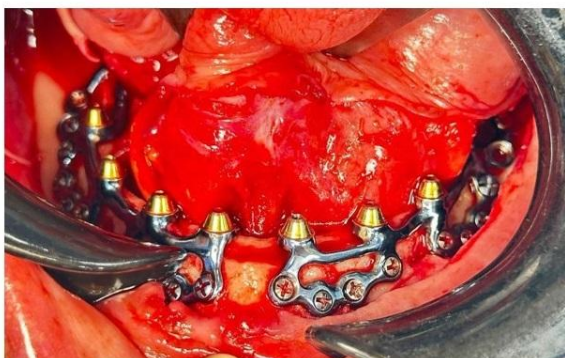
*Figure 10. A. Virtual planning of the right maxillary subperiosteal implant, illustrating the digital planning phase. B and C. Custom-made Titanium subperiosteal implants.*



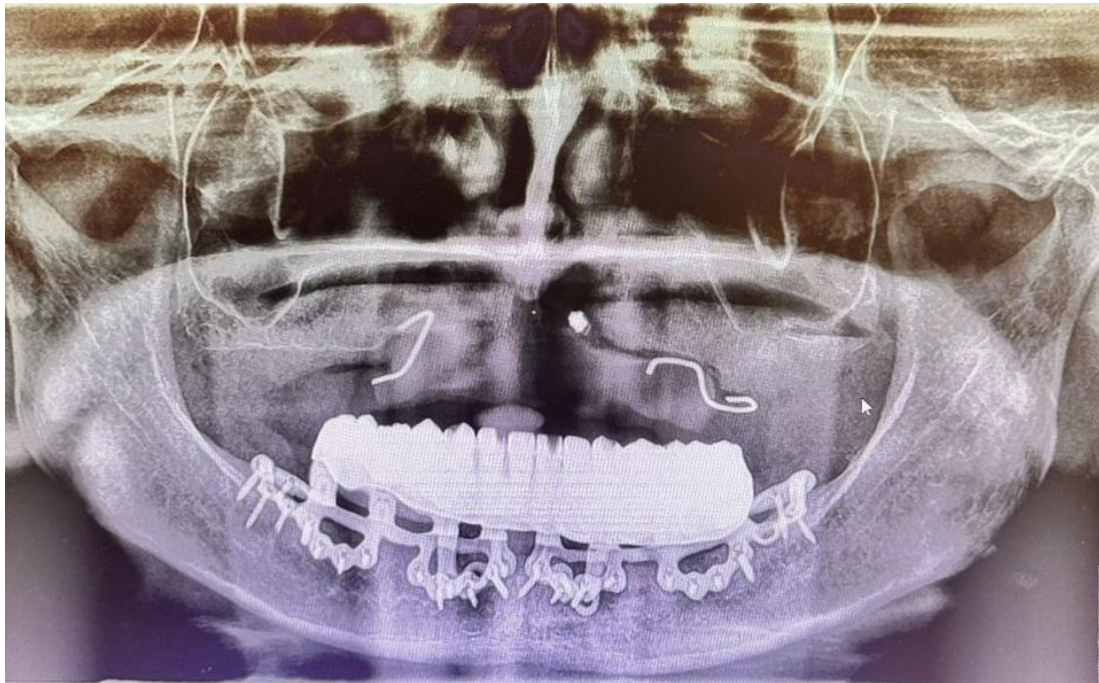
**Figure 11.** Postoperative orthopantomogram demonstrating a patient-specific subperiosteal implant positioned in the upper right atrophic maxilla, showing stable fixation and appropriate anatomical adaptation following surgical placement.



**Figure 12.** A. Intraoperative view of a custom-made osteotomy guide seated on the atrophic mandible (left), illustrating precise adaptation to the osseous contour and highlighting the implant design and tissue interface. B. Osteotomy guide and explanted alveolar bone (right).



*Figure 13. Intraoperative photograph demonstrating mandibular reconstruction with a custom-made titanium subperiosteal implant and multi-unit abutments. The surgical field was exposed via a transoral approach, showing multiple monocortical screws. Intra-operative clinical photograph showing immediate loading with temporary acrylic bridge.*

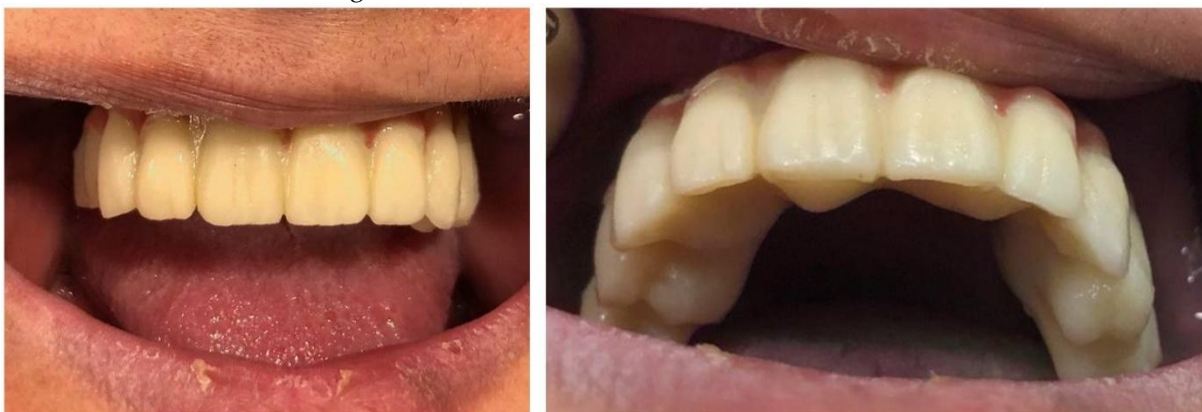

*Figure 14. Two years follow-up Orthopantomogram demonstrating a completely edentulous mandibular arch with associated alveolar ridge resorption.*

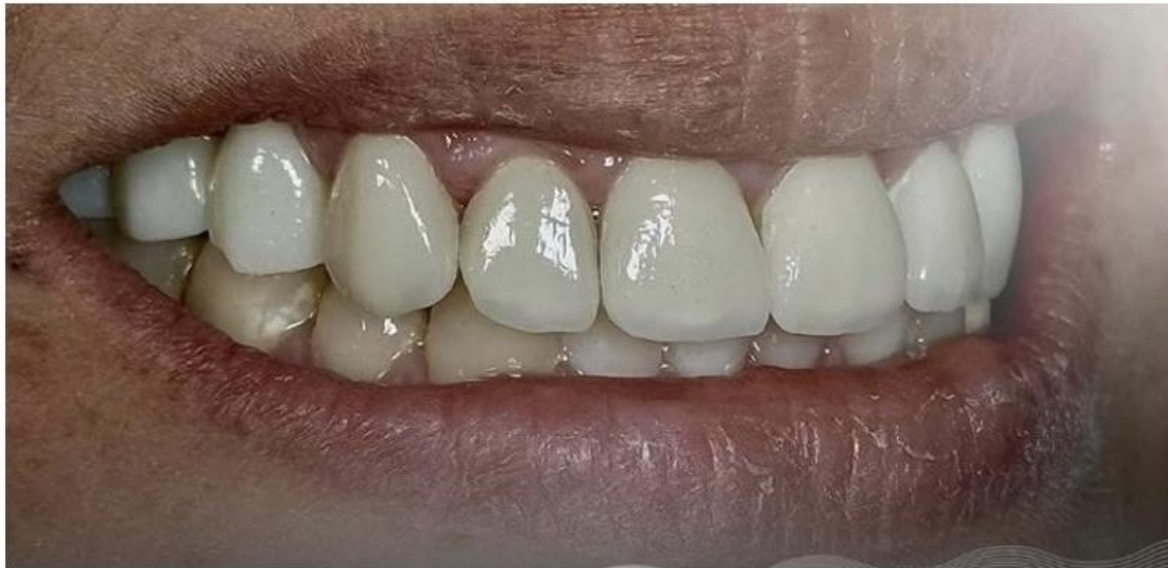The mandibular arch was rehabilitated with a full arch, implant-supported fixed prosthesis. Twenty-one endosseous screw-type dental implants are present in the interforaminal and posterior mandibular regions, supporting a custom-made titanium subperiosteal implant with multi-unit abutments. The OPG exhibits an anteroposterior distribution minimizing anatomical constraints. The peri-implant bone levels appear stable, with no evident radiolucency suggestive of peri-implant pathology.

#### **Prosthetic Rehabilitation**

All patients received screw-retained fixed hybrid prostheses. Immediate loading was applied to cases with adequate primary stability. Provisional acrylic prostheses were replaced with definitive zirconia or titanium frameworks after three to six months as illustrated in Figures 15 and 16.



*Figure 15. Prosthetic phase of graft-less implant rehabilitation. Frontal (left) and occlusal (right) intraoral views showing the definitive fixed full arch, implant-supported prosthesis.*



*Figure 16. Clinical photos for a two-years follow-up demonstrating the successful rehabilitation with a subperiosteal implant for the lower arch.*

#### ***Follow-Up and Outcome Measures***

Patients were followed for periods ranging from 1 to 25 months, with a mean follow-up duration of 14.8 months. Outcome assessment focused on implant survival and evidence of successful osseointegration, peri-implant soft tissue health, and prosthetic stability and functional performance throughout the observation period. In addition, the occurrence of complications, including sinusitis, implant or framework exposure, infection, and paraesthesia, were systematically recorded. Patient-reported satisfaction was also evaluated using a visual analog scale (VAS) ranging from 0 to 10.

#### **Results**

##### ***Implant Survival***

Twenty-two of the 24 implants remained functional and osseointegrated, yielding a survival rate of 92%.

##### ***Complications***

Complications observed during the study were limited and modality-specific. Among patients treated with zygomatic implants, one case of transient oral–antral communication was recorded, which resolved spontaneously within two weeks without the need for further intervention. No major complications were reported in association with pterygoid implants. In the subperiosteal implant group, one patient experienced minor plate exposure that was successfully managed through local flap advancement, while another case presented with buccal wound dehiscence that failed to achieve complete healing. Importantly, no cases of chronic sinusitis, implant mobility, or prosthetic failure were observed across any of the implant modalities.

##### ***Patient Satisfaction***

All patients reported high satisfaction (mean VAS 9.1/10) with improved mastication, phonetics, and esthetics. (Table 1) presents a comparative summary of zygomatic, pterygoid, and subperiosteal implants, highlighting indications, follow-up duration, complication profiles, implant survival, and patient satisfaction, thereby illustrating comparable clinical outcomes across the three graft-less rehabilitation strategies.

*Table 1. Comparative summary of implant distribution, clinical indications, follow-up period, complications, implant survival, and patient satisfaction for zygomatic, pterygoid, and subperiosteal implants used in graft-less rehabilitation of severely atrophic jaws.*

Parameter	Zygomatic	Pterygoid	Subperiosteal
Number of implants	11	7	6
Main indication	Severe posterior maxillary atrophy	Posterior maxilla without sinus lift	Extreme atrophy, poor bone quality
Mean follow-up	18 mo	14 mo	12 mo
Complications	1 (oral-antral)	0	2 (plate exposure)
Implant survival	92%	92%	92%
Patient satisfaction (VAS)	9.2	9.0	9.0

## Discussion

The present observational study supports the efficacy of graft-less implant protocols in managing severe maxillary and mandibular atrophy. Across all three implant modalities, survival rates exceeded 92%, consistent with previous reports [16-20].

Zygomatic implants demonstrated excellent stability and aesthetic outcomes, aligning with outcomes reported by Chrcanovic et al., who found cumulative survival rates above 96% in a 10-year review [21]. Their ability to anchor in dense zygomatic bone allows for immediate loading and avoids sinus grafting, reducing treatment time and morbidity [22]. For this reason, for patients who have undergone partial or total maxillectomy, zygomatic implants can serve as a reconstructive option in place of conventional approaches such as non-implant-supported obturators or microvascular free-flap reconstructions. Reported failure rates generally range from 0% to 4.8%. The incorporation of smooth surface regions in specific segments of zygomatic implants is primarily intended to enhance peri-implant soft tissue health. These polished areas reduce the risk of infection and soft tissue irritation in regions that are not in direct contact with bone, whereas a roughened surface is typically reserved for the apical portion to facilitate osseointegration [23, 24].

### Advantages of Smooth Surface Design

Smooth, polished parts of the implant surfaces exhibit reduced bacterial adhesion compared with roughened surfaces, thereby limiting plaque accumulation and biofilm formation. This characteristic contributes to a lower incidence of bacterial-related complications, including peri-implantitis. Additionally, in hybrid-design zygomatic implants, the smooth or machined surface is commonly applied to the portion traversing or adjacent to the maxillary sinus and surrounding soft tissues. This design minimizes mechanical irritation of the sinus membrane and reduces inflammatory responses in adjacent tissues [23,24].

The smooth collar or cervical region of the implant may also promote stable soft tissue attachment, facilitating the formation of a biological seal. This seal can impede apical epithelial migration and restrict bacterial penetration into deeper peri-implant tissues, further decreasing infection risk. Moreover, by reducing tissue irritation and limiting bacterial ingress along the implant trajectory through the sinus region, smooth surface designs are associated with a decreased likelihood of postoperative sinusitis. From a maintenance perspective, smooth surfaces are easier to clean, supporting improved long-term hygiene for both patients and clinicians [23, 24].

### Hybrid Surface Design Concept

Contemporary zygomatic implants commonly employ a hybrid surface configuration. The apical segment, which engages the dense zygomatic bone, is typically roughened through techniques such as sandblasting and acid etching to enhance primary stability and promote rapid osseointegration. In contrast, the coronal or cervical portion, which interfaces with softer crestal bone and peri-implant soft tissues, is often smooth or machined to optimize soft tissue compatibility. This strategic combination of surface characteristics capitalizes on the biological advantages of each design, contributing to both long-term implant stability and the preservation of surrounding hard and soft tissues [23, 24].

However, placement of zygomatic implants has been linked to a range of biological complications [25-27]. Among these, sinusitis and other sinus-related conditions emerged as the most reported adverse outcomes, with 58% of the reviewed studies documenting such complications. Oroantral fistula and peri-implantitis were also frequently observed, being reported in 25.5% and 15% of the included publications, respectively. Consequently, these conditions represent the

second and third most prevalent biological complications associated with zygomatic implant placement for orofacial reconstruction. Additional biological complications described in the literature include paraesthesia, mucositis, perforation of the Schneiderian membrane, orbital cavity involvement, fracture of the zygomatic bone, cutaneous fistula or fenestration, intracerebral penetration of the implant, and hematoma formation. Comparable surgical complications have likewise been documented by other investigators [28,29]. In our series of zygomatic implant cases, only one patient experienced a maxillary sinus complication. In addition, soft-tissue proliferation around the implants may result in deep peri-implant pockets, increasing susceptibility to peri-implantitis.

However, in maxillae reconstructed after tumour resection, failures have been documented at much higher levels, reaching 21.43% (a survival rate of 78.57%). Several factors may contribute to this increased risk, including recurrent infections or tumour recurrence, limited residual bone volume for achieving stable anchorage and osseointegration, and excessive biomechanical loading in large maxillary defects.

Radiotherapy further compromises outcomes, as its harmful effects on bone healing are well recognized and can reduce zygomatic implants' survival rates [30]. Consequently, to minimize the likelihood of implant failure in resected maxillae, the placement of zygomatic implants is now considered contraindicated in medically compromised patients, individuals with a previous history of head and neck radiation, and those with general contraindications for implant surgery [31,32].

Pterygoid implants provided a reliable posterior anchor, particularly beneficial for patients with limited residual ridge height but intact posterior maxillary bone. Recent studies by Aparicio et al. and others have demonstrated survival rates ranging from 95–100%, with minimal complications and high patient satisfaction [33,34].

Subperiosteal implants have historically been associated with complications such as infection and exposure. However, the integration of digital planning and additive manufacturing has renewed interest in this approach. Modern custom-fit subperiosteal frameworks exhibit favourable results and improved soft-tissue compatibility, as confirmed by Balshi et al. [35,36] and Abduo & Lyons [37].

The minimal complications observed in this study (two minor events) underscore the safety of graft less protocols when executed with proper planning and surgical expertise. The absence of implant loss or chronic sinusitis corroborates reports that careful trajectory planning and avoidance of vital structures are key to long-term success [38].

The clinical decision-making process among the three treatment approaches should consider multiple factors, including the availability of bone and associated anatomical constraints, patient-related comorbidities such as sinus health and systemic conditions, including diabetes mellitus, as well as the level of surgical expertise and the resources available at the treating facility. In addition, patient preferences regarding the degree of surgical invasiveness and the associated financial considerations should be carefully evaluated when selecting the most appropriate implant modality. This series highlights that graft-less techniques are especially advantageous in low-resource environments such as Libya, where bone graft materials and hospital infrastructure may be limited.

### **Limitations**

The study's limitations include its non-randomized design, small sample size, and variable follow-up periods. Radiographic bone stability was not quantitatively analyzed, and histological confirmation of osseointegration was not performed. Future prospective studies with standardized protocols and longer follow-ups are warranted.

### **Conclusion**

Pterygoid, zygomatic, and subperiosteal implants provide reliable alternatives for the rehabilitation of severely atrophic jaws without bone grafting. All three techniques achieved full osseointegration and excellent patient satisfaction with minimal complications. The choice of implant should be tailored to the individual patient's anatomical and systemic profile. Graft-less rehabilitation offers a cost-effective, less invasive, and highly predictable treatment modality suitable for use in both advanced and resource-limited clinical settings. In this observational series of 15 patients, graft-less rehabilitation achieved a 92% implant survival rate (22/24 implants), a low complication rate limited to minor, self-resolving events (2 cases, 13.3%), high patient satisfaction (mean VAS 9.1/10), and enabled immediate or early loading in selected cases, thereby quantitatively supporting its predictability and reduced surgical morbidity compared with graft-based protocols.

### Conflict of Interest

None declared.

### Funding

No external funding was received for this study.

### References

1. Albrektsson T, Zarb G, Worthington P, Eriksson AR. The long-term efficacy of currently used dental implants: a review and proposed criteria of success. *Int J Oral Maxillofac Implants.* 1986;1(1):11-25.
2. Esposito M, Grusovin MG, Felice P, Karatzopoulos G, Worthington HV, Coulthard P. Interventions for replacing missing teeth: horizontal and vertical bone augmentation techniques for dental implant treatment. *Cochrane Database Syst Rev.* 2009;2009(4):CD003607.
3. Chiapasco M, Abati S, Romeo E, Vogel G. Clinical outcome of autogenous bone blocks or guided bone regeneration with e-PTFE membranes for the reconstruction of narrow edentulous ridges. *Clin Oral Implants Res.* 1999;10(4):278-88.
4. Starch-Jensen T, Jensen JD. Maxillary sinus floor augmentation: a review of selected treatment modalities. *J Oral Maxillofac Res.* 2017;8(3):e3.
5. Cooper LF, Shirazi S. Osseointegration—the biological reality of successful dental implant therapy: a narrative review. *Front Oral Maxillofac Med.* 2021;4.
6. Aparicio C, Manresa C, Francisco K, Claros P, Alández J, González-Martín O, et al. Zygomatic implants: indications, techniques and outcomes, and the zygomatic success code. *Periodontol 2000.* 2014;66(1):41-58.
7. Avila-Ortiz G, Vegh D, Mukaddam K, Galindo-Moreno P, Pjetursson B, Payer M. Treatment alternatives for the rehabilitation of the posterior edentulous maxilla. *Periodontol 2000.* 2023;93(1):183-204.
8. Chrcanovic BR, Albrektsson T, Wennerberg A. Survival and complications of zygomatic implants: an updated systematic review. *J Oral Maxillofac Surg.* 2016;74(10):1949-64.
9. Aalam AA, Krivitsky-Aalam A, Kurtzman GM, Mahesh L. The severely atrophic maxilla: decision making with zygomatic and pterygoid dental implants. *J Oral Biol Craniofac Res.* 2023;13(2):202-6.
10. Jivraj S, editor. Graftless solutions for the edentulous patient. *BDJ Clinician's Guides.* New York: Springer; 2018.
11. Malevez C, Abarca M, Durdu F, Daelemans P. Clinical outcome of 103 consecutive zygomatic implants: a 6-48 months follow-up study. *Clin Oral Implants Res.* 2004;15(1):18-22.
12. Galán Gil S, Peñarrocha Diago M, Balaguer Martínez J, Marti Bowen E. Rehabilitation of severely resorbed maxillae with zygomatic implants: an update. *Med Oral Patol Oral Cir Bucal.* 2007;12(3):E216-20.
13. Polido WD, Machado-Fernandez A, Lin WS, Aghaloo T. Indications for zygomatic implants: a systematic review. *Int J Implant Dent.* 2023;9(1):17.
14. Gasparini G, Todaro M, De Angelis P, Boniello R, Saponaro G, Rella E, et al. Clinical outcomes of CAD-CAM subperiosteal implants for the rehabilitation of atrophic jaws. *Dent J (Basel).* 2024;12(8).
15. Arshad M, Khoramshahi N, Shirani G. Additively custom-made 3D-printed subperiosteal implants for the rehabilitation of the severely atrophic maxilla (a case report). *Clin Case Rep.* 2023;11(11):e8135.
16. Lorusso F, Conte R, Inchingolo F, Festa F, Scarano A. Survival rate of zygomatic implants for fixed oral maxillary rehabilitations: a systematic review and meta-analysis comparing outcomes between zygomatic and regular implants. *Dent J (Basel).* 2021;9(4):43.
17. Brennand Roper M, Vissink A, Dudding T, Pollard A, Gareb B, Malevez C, et al. Long-term treatment outcomes with zygomatic implants: a systematic review and meta-analysis. *Int J Implant Dent.* 2023;9(1):21.
18. Goh R, Vaquette C, Breik O, Ivanovski S, Batstone M. Subperiosteal implants: a lost art worth revisiting? *Clin Implant Dent Relat Res.* 2025;27(2):e70025.
19. Tian Y, Chen C, Xu X, Wang J, Hou X, Li K, et al. A review of 3D printing in dentistry: technologies, affecting factors, and applications. *Scanning.* 2021;2021:9950131.
20. Deshwal R, Salaria SK, Deshwal N. Graftless immediate implant placement in the extremely atrophic posterior maxillary site utilizing lateral window and tenting approach followed by surgical aided closure: a case report with 1-year follow-up. *J Indian Soc Periodontol.* 2024;28(6):701-5.
21. Howe MS, Keys W, Richards D. Long-term (10-year) dental implant survival: a systematic review and sensitivity meta-analysis. *J Dent.* 2019;84:9-21.
22. Aparicio C, Polido WD, Chow J, David L, Davo R, Jose De Moraes E, et al. Identification of the pathway and appropriate use of four zygomatic implants in the atrophic maxilla: a cross-sectional study. *Int J Oral Maxillofac Implants.* 2021;36(4):773-81.

23. Aleksandrowicz P, Kusa-Podkańska M, Tomkiewicz W, Kotuła L, Perek J, Wysokińska-Miszczuk J. Platform switch hybrid zygoma implants improve prosthetics and marginal bone protection after extra-sinus placement. *Clin Implant Dent Relat Res.* 2020;22(2):186-92.
24. Kumar V, Aeran M, Sani A. From surface to success: how implant surfaces shape osseointegration. *IP Int J Periodontol Implantol.* 2024;9(2):58-63.
25. Mavriqi L, Lorusso F, Conte R, Rapone B, Scarano A. Zygomatic implant penetration to the central portion of orbit: a case report. *BMC Ophthalmol.* 2021;21(1):121.
26. Liaw K, Delfini RH, Abrahams JJ. Dental implant complications. *Semin Ultrasound CT MR.* 2015;36(5):427-33.
27. Turkyilmaz I. A proposal of new classification for dental implant complications. *J Contemp Dent Pract.* 2018;19(8):1025-33.
28. Di Cosola M, Ballini A, Zhurakivska K, Ceccarello A, Nocini R, Malcangi A, et al. Retrospective analysis of clinical and radiologic data regarding zygomatic implant rehabilitation with a long-term follow-up. *Int J Environ Res Public Health.* 2021;18(24):13105.
29. Annibali S, Cristalli MP, Dell'Aquila D, Bignozzi I, La Monaca G, Pilloni A. Short dental implants: a systematic review. *J Dent Res.* 2012;91(1):25-32.
30. Reher P, Chrcanovic BR, Springett R, Harris M. Near infrared spectroscopy: a diagnostic tool to evaluate effects of radiotherapy in the mandible? *Spectroscopy.* 2012;26(1):11-32.
31. Davo R, Malevez C, Rojas J. Immediate function in the atrophic maxilla using zygoma implants: a preliminary study. *J Prosthet Dent.* 2007;97(6 Suppl):S44-51.
32. Ramezanzade S, Yates J, Tuminelli FJ, Keyhan SO, Yousefi P, Lopez-Lopez J. Zygomatic implants placed in atrophic maxilla: an overview of current systematic reviews and meta-analysis. *Maxillofac Plast Reconstr Surg.* 2021;43(1):1.
33. Tao B, Wang N, Ling X, Ye L, Wu Y. Comparison of the accuracy of dynamic navigation and the free hand approaches in the placement of pterygoid implants in the completely edentulous maxilla: an in vitro study. *J Dent Sci.* 2024;19(4):2341-7.
34. Bidra AS, May GW, Tharp GE, Chambers MS. Pterygoid implants for maxillofacial rehabilitation of a patient with a bilateral maxillectomy defect. *J Oral Implantol.* 2013;39(1):91-7.
35. Balshi TJ, Wolfinger GJ, Pellecchia R, Reiger W, Blakely JW, Balshi SF, et al. 9-year follow-up on maxillofacial implant-supported framework designed to accommodate childhood growth. *J Prosthodont.* 2022;31(7):551-61.
36. Herce-López J, Pingarrón MDC, Tofé-Povedano Á, García-Arana L, Espino-Segura-Illa M, Sieira-Gil R, et al. Customized subperiosteal implants for the rehabilitation of atrophic jaws: a consensus report and literature review. *Biomimetics (Basel).* 2024;9(1):31.
37. Schubert O, Schweiger J, Stimmelmayer M, Nold E, Güth JF. Digital implant planning and guided implant surgery—workflow and reliability. *Br Dent J.* 2019;226(2):101-8.
38. Cîmpean CR, Ormenișan A, Burcea A, Bogdan-Andreescu CF, Bănățeanu AM, Poalelungi CV, et al. Implant-based rehabilitation strategies for the severely atrophic maxilla. *Rom J Oral Rehabil.* 2025;17(1).